

# بعض الحالات الجراحية في مستشفى اليرموك التعليمي

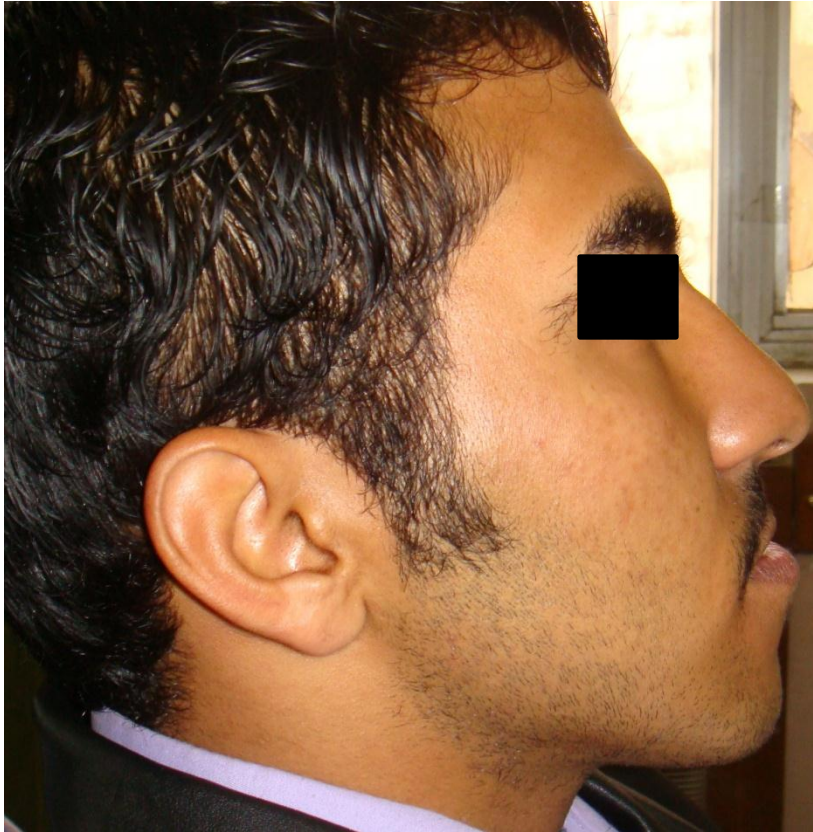م.د. سلوان يوسف

BDS, FIBMS

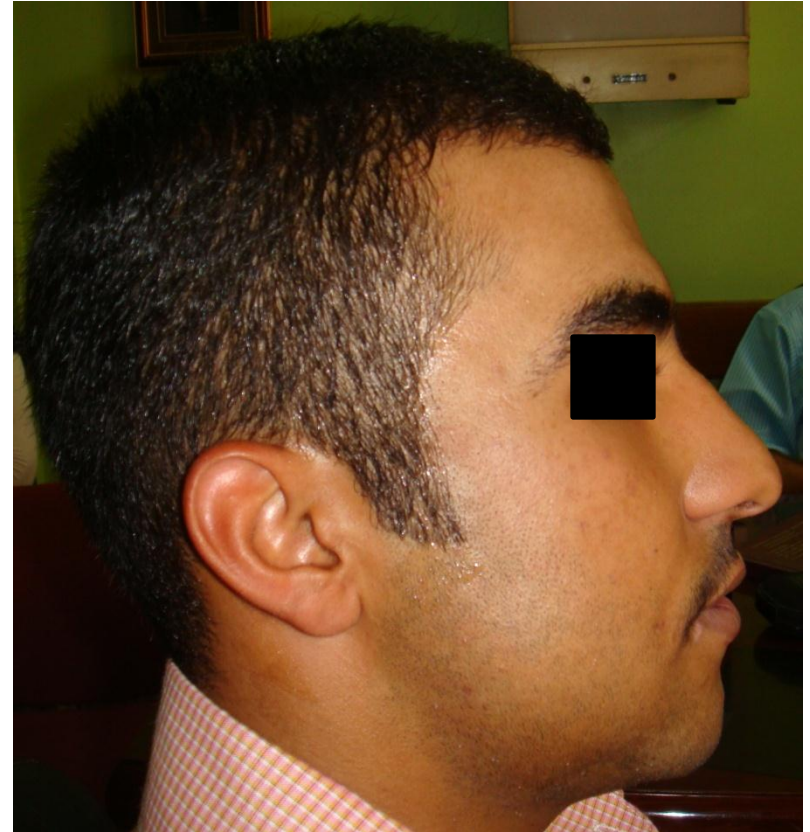فرع جراحة الفم والوجه والفكين

كلية طب الاسنان/جامعة بغداد

# A case of mandibular prognathism treated by bilateral sagittal split osteotomy

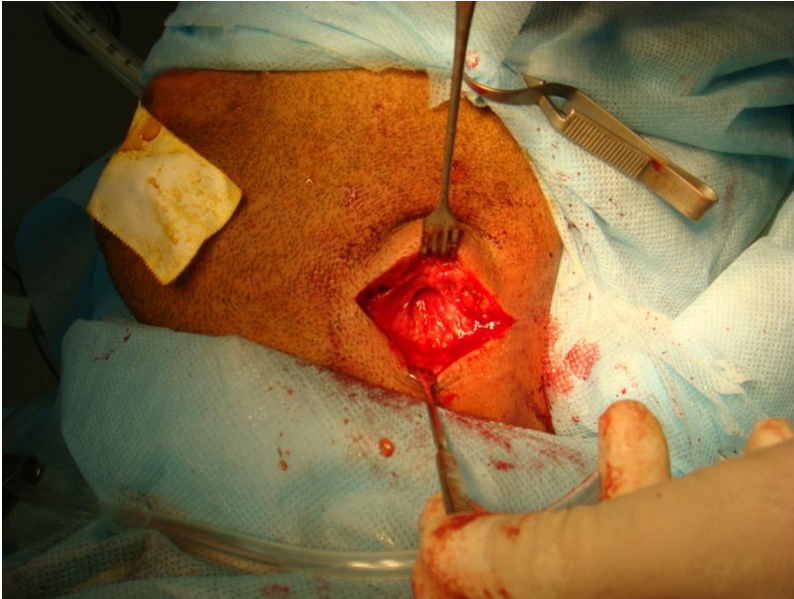
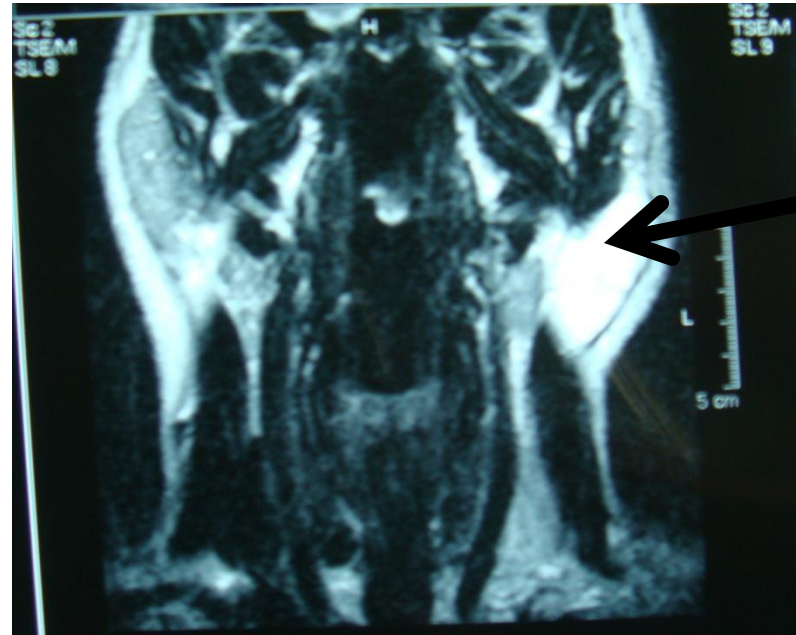
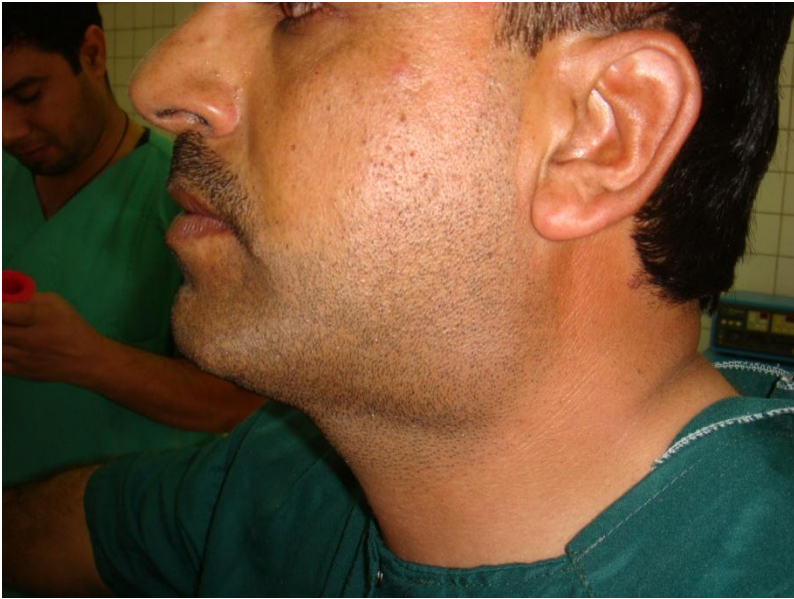
Before

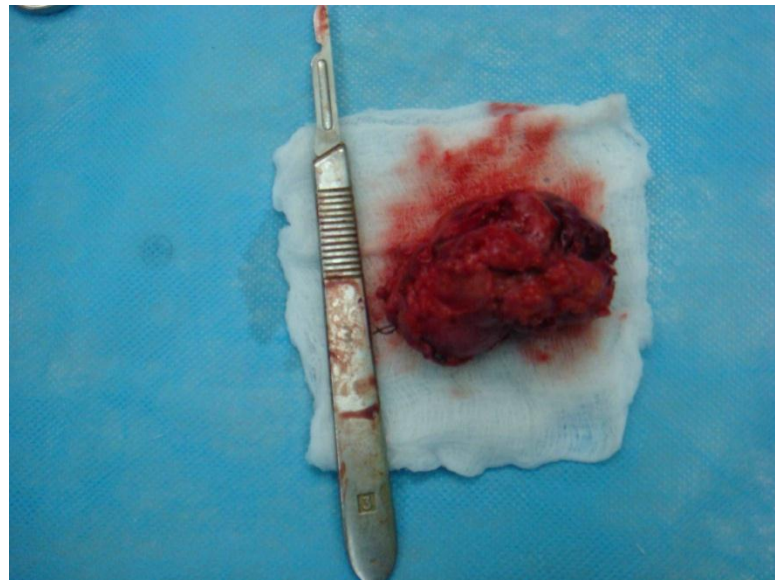
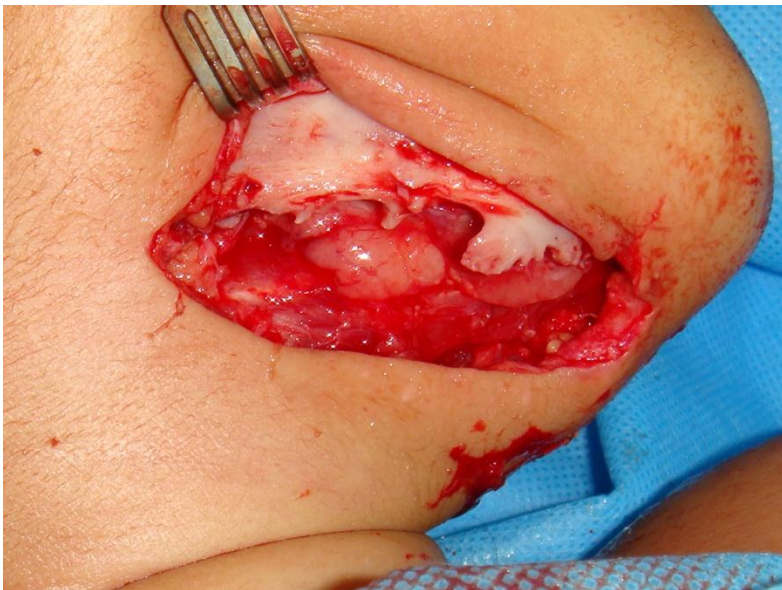
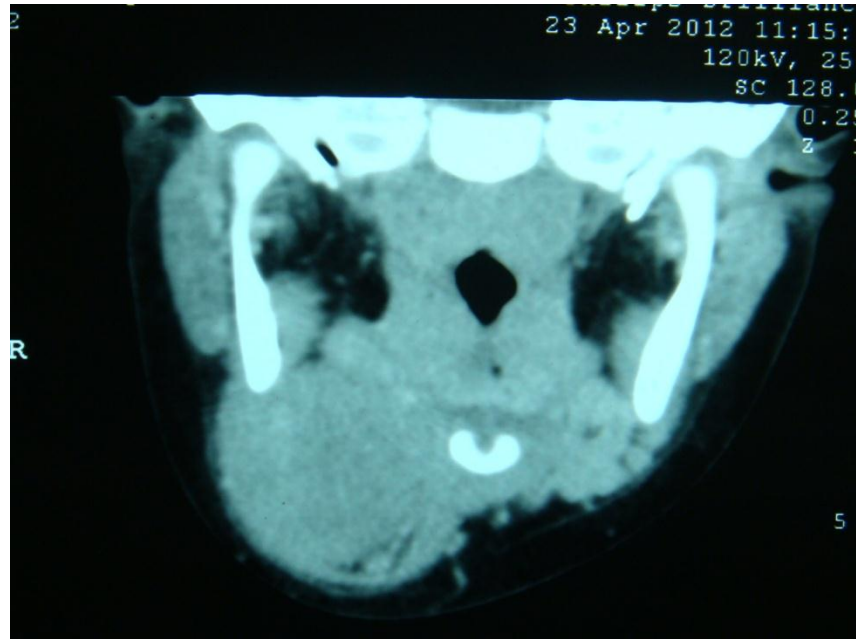
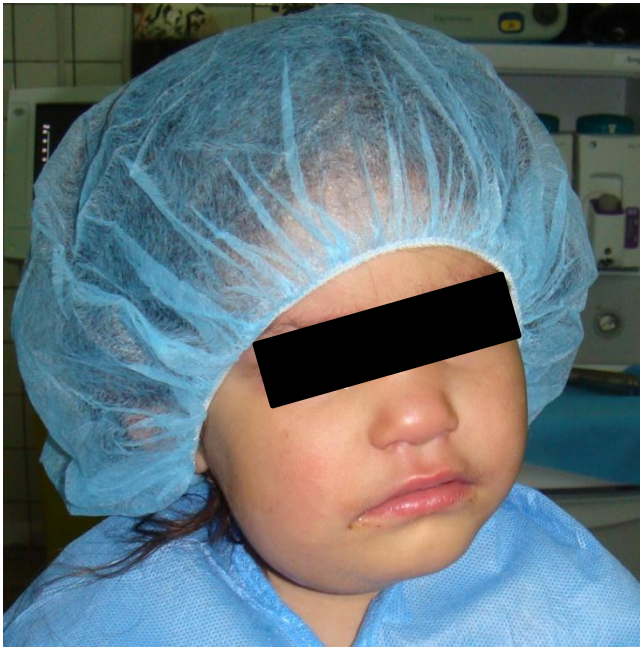After

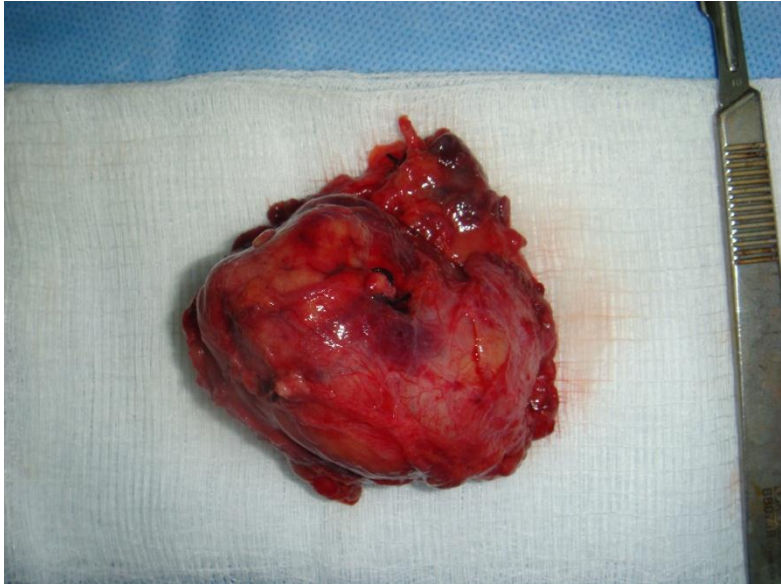
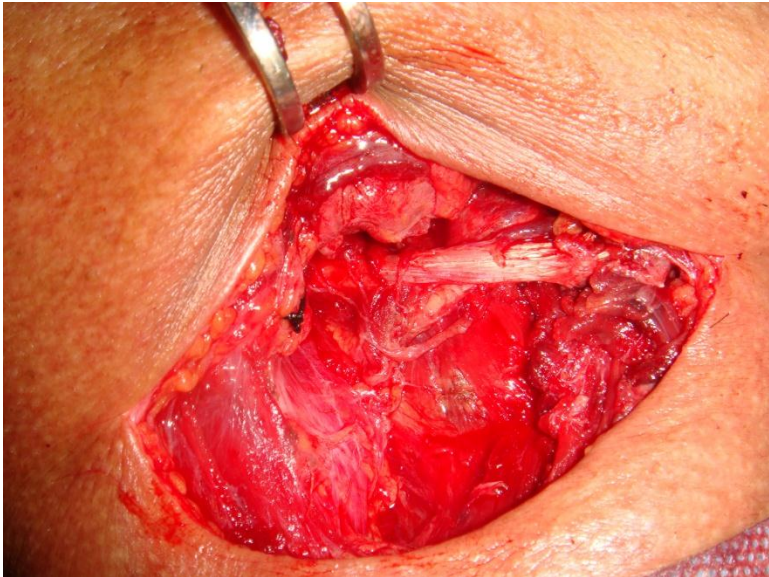
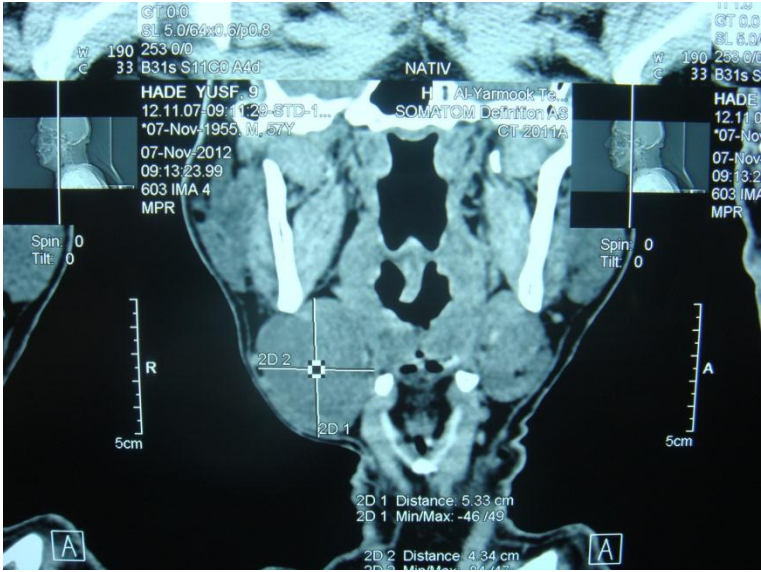
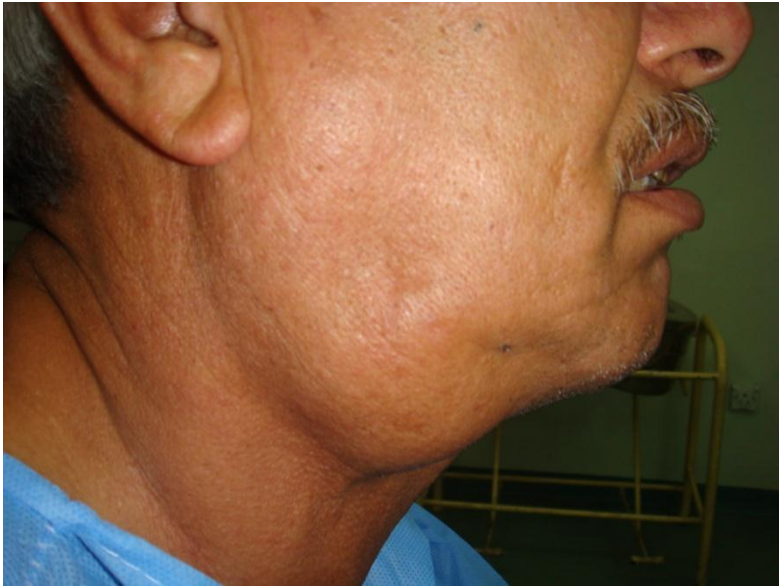## A case of submandibular mass: Lipoma



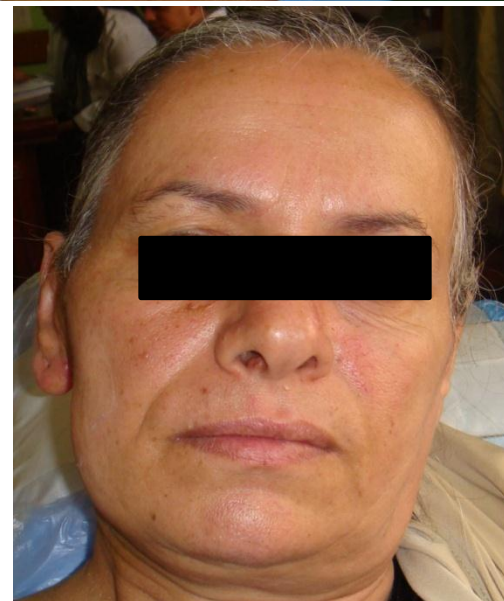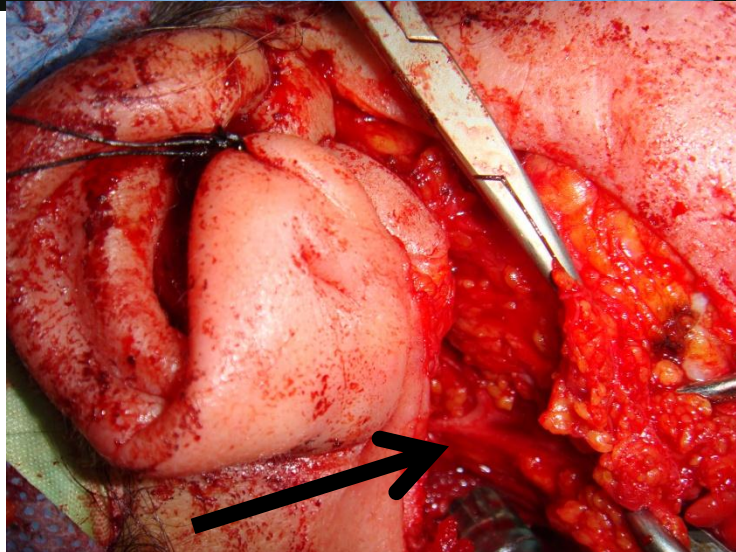
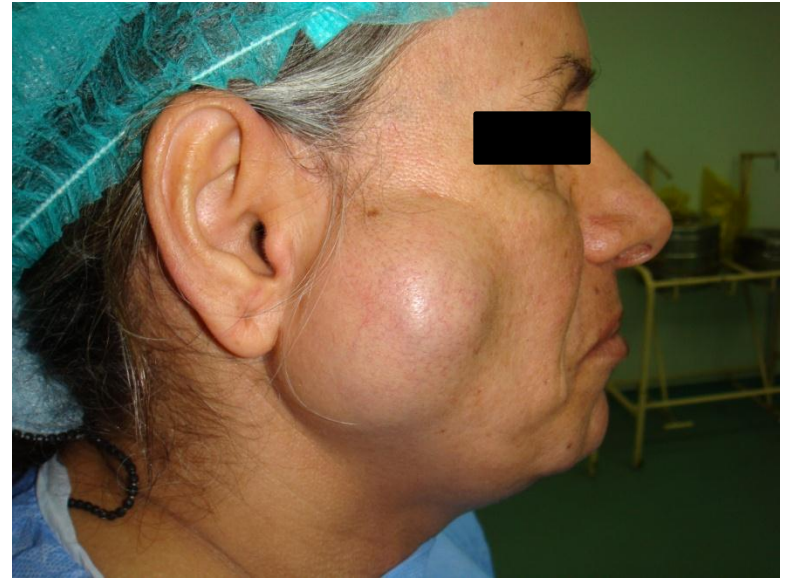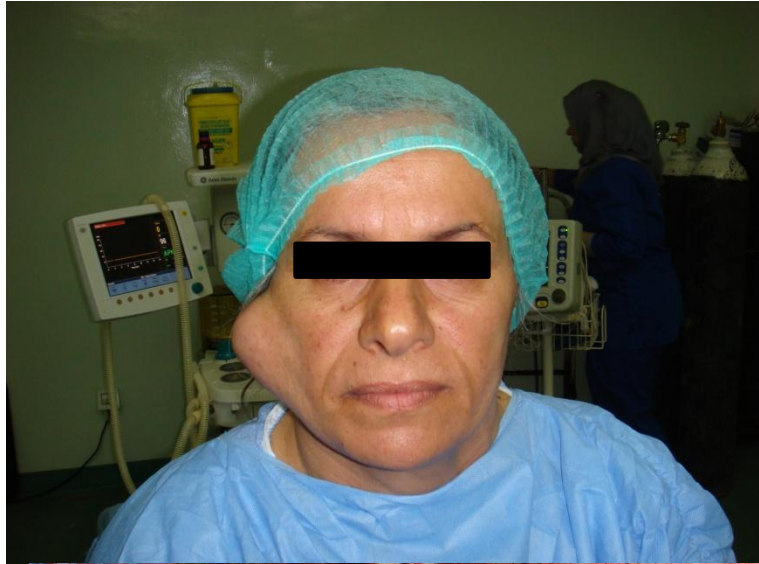# A case of submandibular mass: Juvenile Fibromatosis



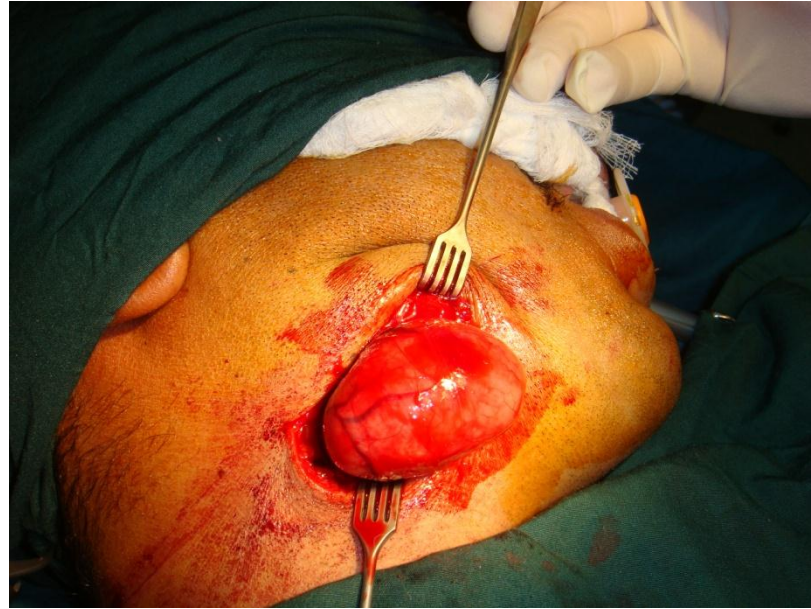
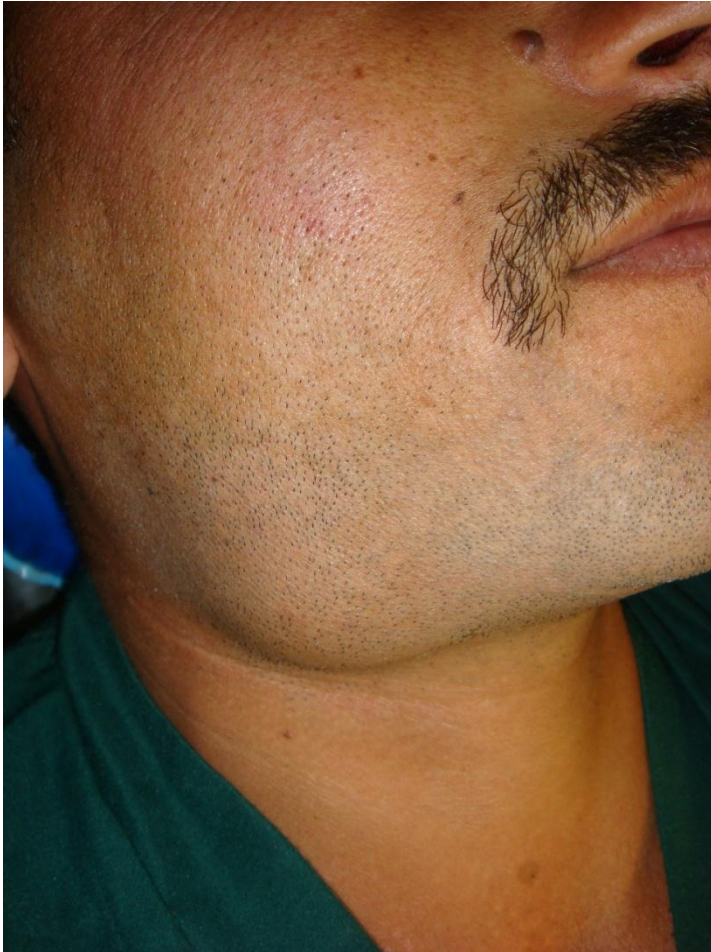# A case of submandibular salivary gland tumor: Pleomorphic adenoma



# A case of monomorphic adenoma of the parotid gland



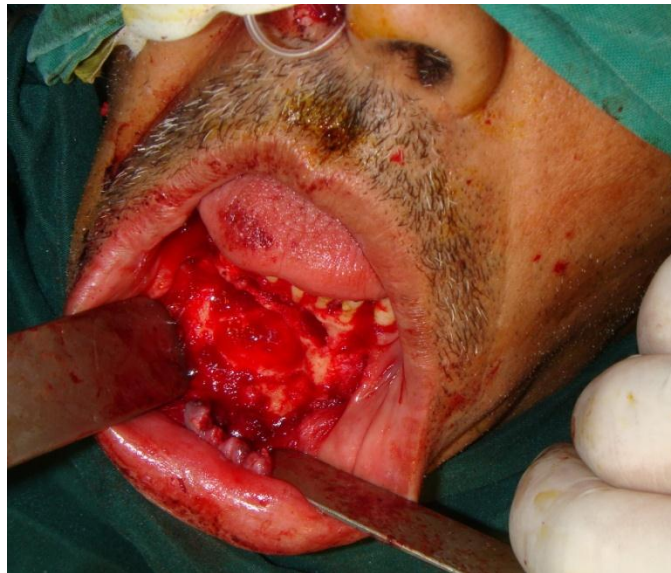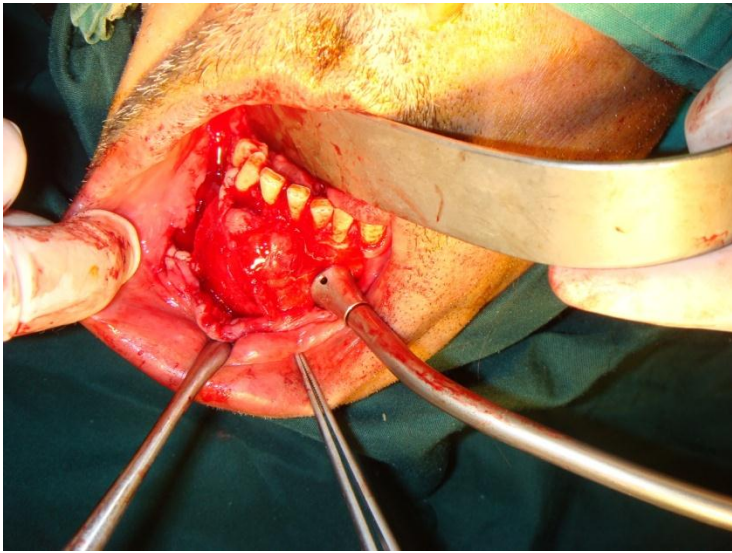
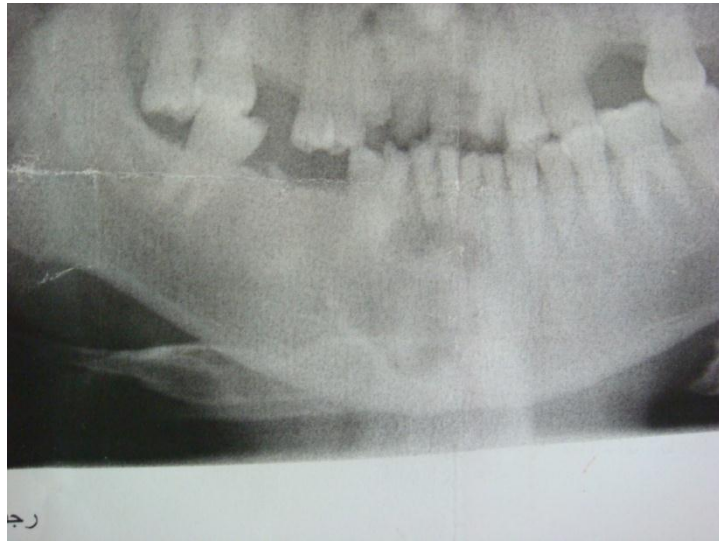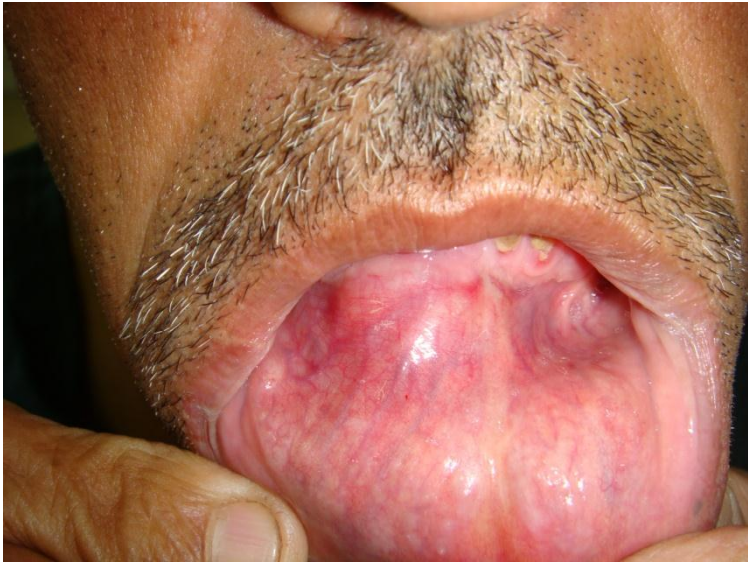## A case of submandibular LAP: Non-Hodgkin's Lymphoma



**Gross:** Single piece of tissue (lymph node) measuring 5x4cm, soft white cut section, Px2.

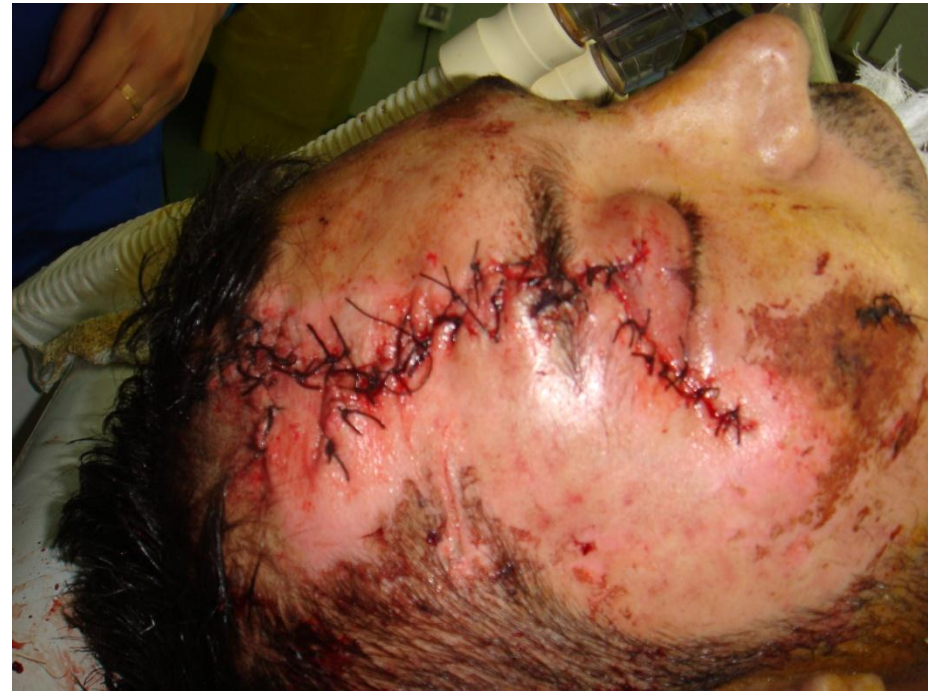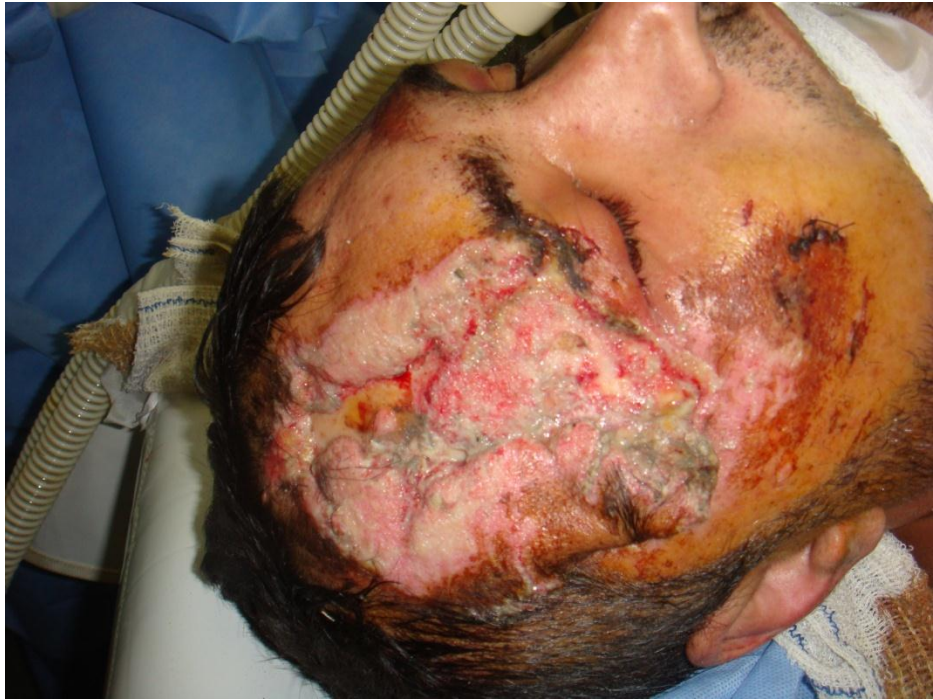**Microscopic:** Section shows total effacement of lymph node architecture by proliferation of small lymphocytes associated with scattered histiocytes. The histological picture is consistent with **Non-Hodgkin's lymphoma (small lymphocytic lymphoma)** of low grade malignancy according to **International Working Formulation.**

# A case of calcifying odontogenic cyst

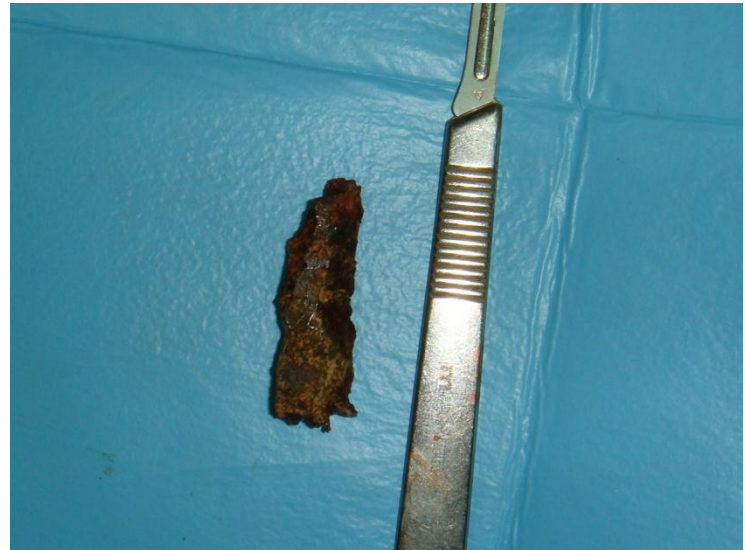
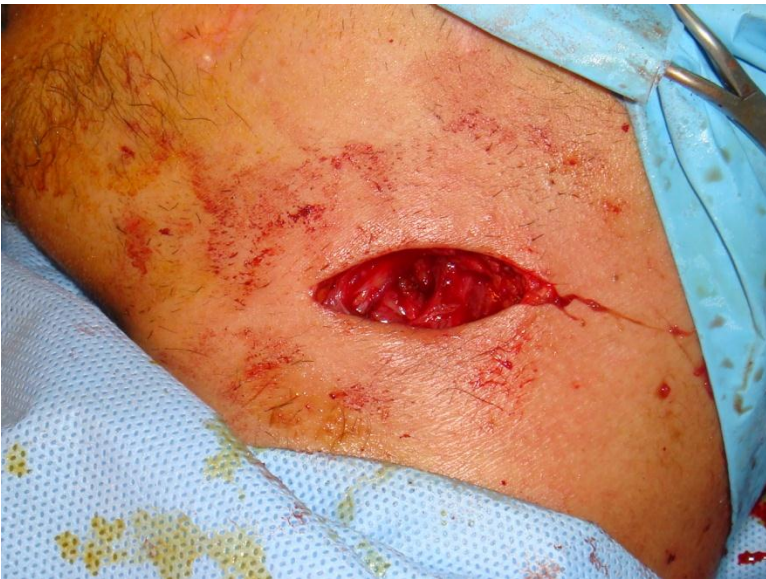
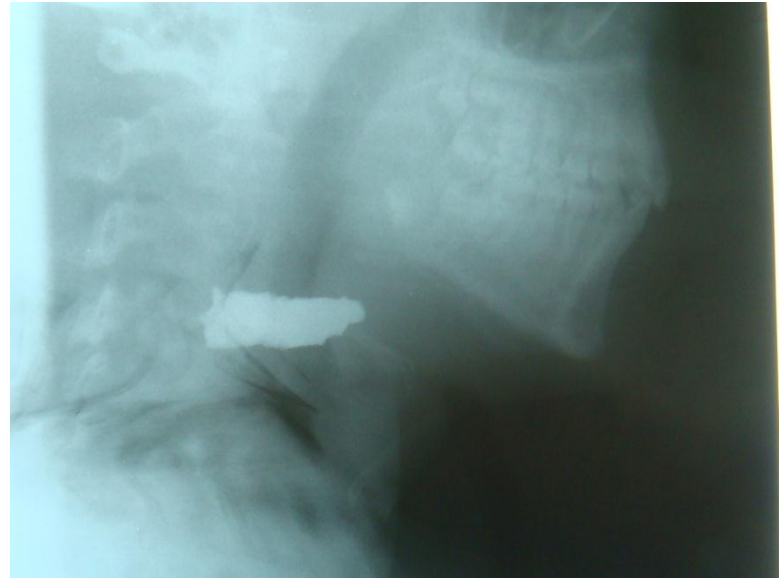
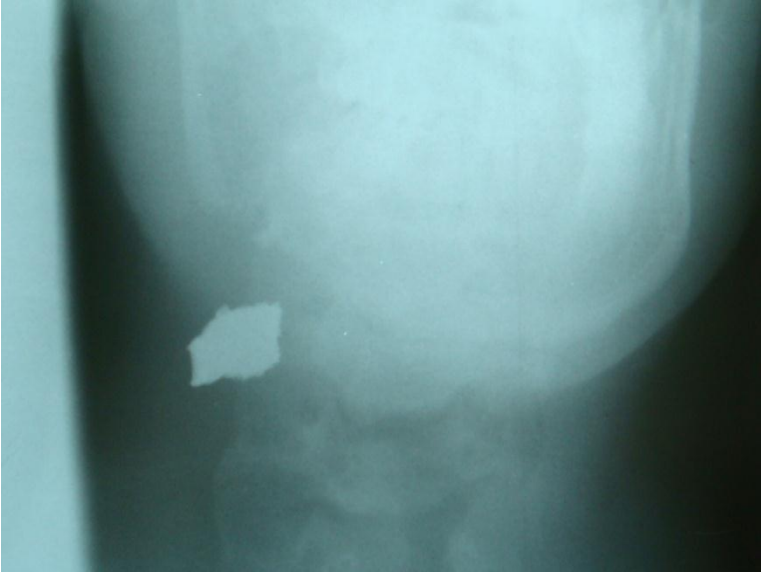

## A case of severe soft tissue injury



# A case of retained foreign body in the neck



# A case of SCC of the dorsum of the tongue treated by partial glossectomy and prophylactic neck dissection

